



DOI: 10.31636/pmjua.v5i3.1

## Innervation Anomalies and Interneural Anastomoses: Is There Clinical Relevance or Not?

Dmytriiev D. V.<sup>1,2</sup>, Dmytriiev K. D.<sup>3</sup>, Lysak E. V.<sup>2</sup>

<sup>1</sup> Department of Anesthesiology and Intensive Care, National Pirogov Memorial University, Vinnytsia

<sup>2</sup> Department of Anesthesiology, Intensive Care and Pain Medicine, Vinnytsia Regional Clinical Endocrinology Center

<sup>3</sup> Department of Propedeutics of Internal Medicine, National Pirogov Memorial University, Vinnytsia

**Abstract.** Failed block could be one of the adverse results of the conductive anaesthesia. There are situations, when in seemingly perfect technique of the block, properly chosen drug, dosage, adjuvant – the block is not achieved (it does not occur or is incomplete or so-called “mosaic block” occurs). It is necessary to remember about atypical or abnormal nerves branching, possible interneural anastomoses, when looking for the possible cause of it. Information about most common types of interneural anastomosis of arm's and leg's long nerves is presented in this article. Knowledge of possible abnormal neural innervation can provide an understanding of inefficacy of some simple blocks, decrease amount of mistakes in data interpretation, that was obtained during electroneuromyographic (ENMG) investigations, improve understanding of clinical pattern in the peripheral nerve injuries, that form anastomosis.

**Key words:** interneural anastomosis, innervation anomalies, conductive anaesthesia, electroneuromyography

### Introduction

Complications of anaesthesia are not predicted or planned function impairment, organs or tissues injury, that were caused by anaesthesiology management of the surgical intervention, that could cause temporary or constant harm to the patient's health or mortality. Conductive anaesthesia is one of the safest types of anaesthesia.

Conductive anaesthesia is a reversible block of nerve impulse transmission in big nerve trunk (nerve, plexus, node) by the injection of local anaesthetic in paraneural space. But according to the Warnet M. data from all the deaths caused by anaesthesia only 3.9% are caused by overdose of local anaesthetics and 6.2% are caused by adverse events.

Complications of conductive anaesthesia could be divided into several groups:

- related to toxic influence of local anaesthetics and adjuvants;
- related to the mistakes in block technique.

But there are sometimes situations, when in seemingly perfect technique of the block, properly chosen drug, dosage, adjuvant – the block is not achieved (it does not occur or is incomplete or so-called “mosaic block” occurs).

It is necessary to remember about atypical or abnormal nerves branching, presence of septum in fascial sheaths of nervous plexus, absence of clear border between in-

nervation zones of certain dermo- or myotome, and anastomosis between of end-branches, possible interneural anastomosis, when certain area is innervated by atypical nerve or by several nerves.

Thompson and Rorie (40) have shown on the basis of anatomical studies and computed tomography that neural fascicular sheath is a complicated structure, that is formed of septum, that goes inside from fascia, which surrounds plexus and nerves. Based on this information authors made a conclusion, that presence of septums could limit the spread of local anaesthetics during the block of nervous plexuses.

On the other hand, Partridge and co-authors have shown, that septums of fascicular sheaths are incomplete and are easily ruined during the injection of local anaesthetics.

### Types of the interneural anastomoses at the forearm level

Martin – Gruber anastomosis (MGA) is well-studied and one of the most prevalent innervation anomaly, that states for the different types of interneural connections between median and ulnar nerve at the level of forearm, the median nerve is a source of communicative branch (its main trunk or branch – anterior interosseal nerve).

This anastomosis was described for the first time by Swedish anatomist R. Martin in 1763 and later in 1870 German anatomist W. Gruber found 38 (15.2 %) of such anastomoses during preparation of 250 forearms (3). MGA usually consists of motor fibers, but could also be mixed sensomotor.

Its prevalence is studied by anatomist as well as by neurophysiologists. In anatomical studies, where more than 200 forearms were prepared, prevalence of MGA consisted 15 % in average (3–5). Same results were obtained by neurophysiologists: according to the data from 2 big neurophysiological studies, were 656 and 1 200 forearms were studied, prevalence of MGA consisted 15 and 10 % correspondingly (1, 6, 7).

Classification of main MGA types was proposed (8, 9):

- type 1 – communicative branch of the median nerve innervate hypothenar together with ulnar nerve (abductor digiti minimi muscle);
- type 2 – communicative branch of median nerve innervates 1<sup>st</sup> dorsal interosseal muscle together with ulnar nerve (is most commonly observed);
- type 3 – communicative branch of median nerve innervates thenar muscles together with ulnar nerve (adductor pollicis muscle or flexor pollicis brevis muscle or both of them);
- combination of different MGA types is rarely observed.

During the investigation of ulnar nerve in patients with normal innervation an amplitude of motor response (M-response) from abductor digiti minimi and 1<sup>st</sup> dorsal interosseal muscle, that is obtained distally (at the level of wrist) by supramaximal stimulus is higher or equal to M-response obtained during supramaximal stimulus in the 2<sup>nd</sup> point (3 cm below the medial epicondyle of the humerus). M-response is absent or of a very low amplitude with primary positive deflection during the investigation of median nerve. Similar situation is observed with adductor pollicis muscle during stimulation of the ulnar nerve (10, 1).

MGA should be suspected in healthy subject during ENMG in the following situations (7, 8):

- when during the investigation of ulnar nerve, M-response obtained from abductor digiti minimi muscle (MGA type 1) or 1<sup>st</sup> dorsal interosseal muscle (MGA type 2) in the 2<sup>nd</sup> stimulation point (3 cm below the medial epicondyle of the humerus) is in 25 % or more smaller than the M-response, obtained distally (at the wrist level), so there is a “false” conductive block (CB) at the level of forearm;
- when during the investigation of median nerve, M-response obtained from the abductor pollicis muscle (MGA type 3), in the 2<sup>nd</sup> stimulation point (at the level of cubital fossa (8, 10)) have and 25 % higher amplitude, that was obtained distally (at the level of wrist) (1).

This is conditioned by the greater amount of axons of the median nerve at the level of cubital fossa (before the separation of communicative branch), than at the level of the wrist (after the separation of communicative branch), while situation is opposite during the investigation of ulnar nerve. “False” conductive block, obtained from the 2<sup>nd</sup> stimulation point of ulnar nerve (3 cm below the medial epicondyle of the humerus), investigated from the abductor digiti minimi muscle in the absence of clinical sign if ulnar nerve injury (is an ENMG finding) requires exclusion of mistakes and MGA (1).

Recommended ENMG protocol if MGA is suspected includes investigation of median and ulnar nerves with 3 muscle leads: abductor pollicis brevis muscle, abductor digiti minimi muscle and 1<sup>st</sup> dorsal interosseal muscle. Stimulation is performed at least in 3 points: at the level of the wrist, elbow joint and shoulder. An innervation anomaly and its type is diagnosed by the investigation.

The rare proximal type of MGA should also be mentioned, when communicative branch separates from the median nerve to the ulnar nerve at the level of elbow joint or lower part of the arm. In this case ENMG pattern of the ulnar nerve is similar to such in cubital syndrome (10, 11), but on the absence of ulnar nerve injury.

## Influence of the anastomosis on the clinical picture of median and ulnar nerves injury

Except the influence on electrophysiological data, connection of median and ulnar nerve at the forearm level influence clinical picture of peripheral nerves of the arm and makes the diagnosis more complicated. If there is a connection between median and ulnar nerves classic pattern of certain nerve injury could become incomplete or abundant.

So, during the injury of median nerve at the level of forearm distally to the separation of MGA, for example carpal tunnel syndrome, symptoms could be incomplete – muscle strength, which are innervated by the fibers consisting anastomosis, is not impaired, also if there is sensor fibers consisting anastomosis, then sensory impairment could not appear or could have slight manifestation.

If ulnar nerve is injured distally to the MGA clinics could be abundant, as except for the ulnar nerve fibers, there are median nerves fibers. Except for the clinical manifestation of ulnar nerve injury, there could weakness of muscles, that are innervated through the anastomosis with median nerve, and if there are sensor fibers consisting anastomosis there will be sensor disorders, that are typical for median nerve injury (27).

Sometimes anastomosis itself can be a place of potential injury due to the compression by adjacent muscles.

Except for the difficulties with diagnosis, presence of interneural anastomoses can lead to the wrong treatment tactics due to the discrepancy between clinical pattern and nerve injury degree. This is very relevant during differential diagnosis of complete or partial nerve injury, as a result of trauma for example.

**Marinacci anastomosis (MA)** – a type of interneural communication between ulnar and median nerves at the level of forearm, the ulnar nerve is a source of communication branch, and thenar muscles (abductor pollicis brevis muscle, superficial head of the flexor pollicis muscle and opponens pollicis muscle) have double innervation (Fig. 1) (14, 15).

This anastomosis was described for the first time by A. Marinacci in 1964. He published a report about patient, who sustained trauma of median nerve at the level of forearm, who had normal thenar muscle function, despite the signs of denervation during needle electromyography of superficial digital flexor (14). MA is rarely determined. According to J. Kimura and co-authors data, its prevalence is just 1.3 % (16). Other authors determined ENMG-signs of MA more often – from 5.0 to 16.7 % (17, 18).

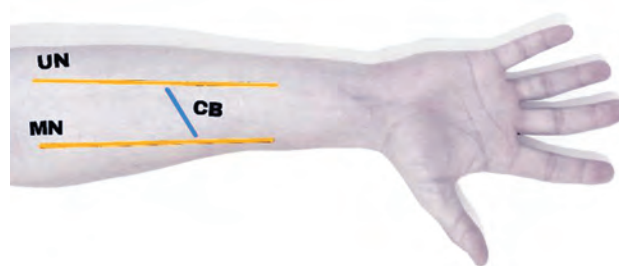


Fig. 1. Schematic image of the Marinacci anastomosis.

CB – communicative branch – Marinacci anastomosis; MN – median nerve; UN – ulnar nerve

MA should be suspected in healthy subject during ENMG in the following situations (17):

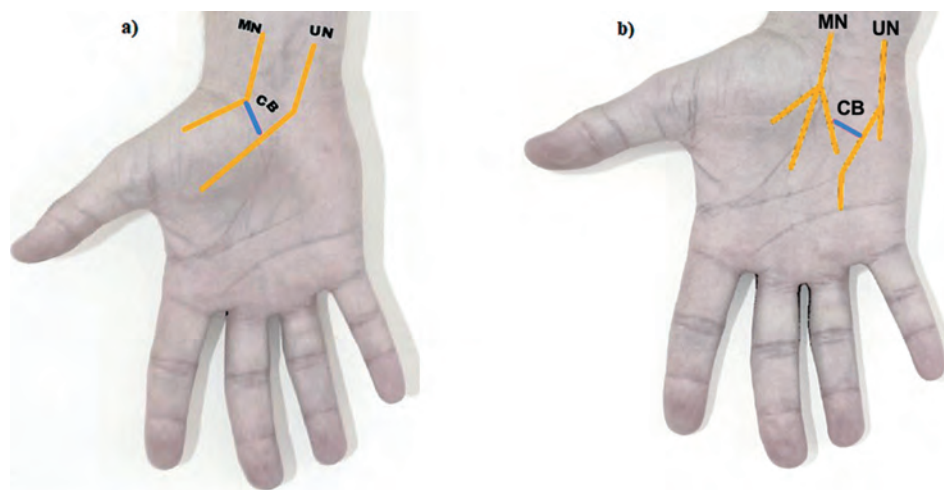
- during investigation of the median nerve from abductor pollicis brevis muscle in the 2<sup>nd</sup> stimulation point M-response is registered at the level of cubital fossa (8, 10), which amplitude is in 20 % or more lower than the M-response amplitude registered distally (at the wrist level), so there is a “false” conductive block at the forearm level;
- during the investigation of ulnar nerve from the abductor pollicis brevis muscle in the 2<sup>nd</sup> stimulation point (3 cm below the medial epicondyle of the humerus (8, 10) M-response with the amplitude of 20 % or more higher than the amplitude of M-response obtained distally (at the level of the wrist).

This conditioned by the fact, that the highest amount of ulnar nerve axons are at the level of cubital fossa (before the separation of communicative branch), than at the level of the wrist (after the separation of communicative branch), while it is opposite during the investigation of median nerve. “False” conductive block, received from the 2<sup>nd</sup> stimulation point of the median nerve (at the level of cubital fossa), investigated from the abductor pollicis brevis muscle – a rare condition with an absence of clinical manifestations of median nerve injury and in all such situations should include exclusion of mistakes (insufficient stimulus during stimulation in the 2<sup>nd</sup> point, incorrect stimulation point, etc.) and MA.

## Types of interneural anastomoses at the wrist level

Riche – Cannieu anastomosis (RCA) is interneural communication between motor fibres of ulnar and median nerves at the wrist level and consists in the prevailing innervation of wrist muscles by the deep motor branch of the ulnar nerve (Fig. 2).

This anastomosis was described in 1897 at the same time by D. Riche and A. Cannieu, so anastomosis was



**Fig. 2. a** – Schematic image of Riche – Cannieu anastomosis: CB – communicative branch – Riche – Cannieu anastomosis (motor fibers); MN – median nerve; UN – ulnar nerve. **b** – Schematic image of Berettini branch: CB – communicative branch – Berettini branch (sensor fibres); MN – median nerve; UN – ulnar nerve

named after them. According to J. Kimura and co-authors data prevalence of RCA is 83 % (16), which surpass the prevalence of MGA in several times. There are publications, the indicates dominant type of inheritance of this type of anastomosis (19).

Neurophysiological pattern can be variable depending on the degree of ulnar nerve participation in the thenar muscles innervation (abductor pollicis brevis muscle, superficial head of the flexor pollicis muscle and opponens pollicis muscle), are normally innervated by median nerve (20). There are 3 types of RCA: formation of so-called “ulnar” hand is typical for the 1<sup>st</sup> type RCA when all hand muscles are innervated by the ulnar nerve, 2<sup>nd</sup> and 3<sup>rd</sup> type are characterized by the different participation of the ulnar nerve in the thenar muscles innervation.

In typical RCA cases (“ulnar” hand) the following pattern could be observed during ENMG in healthy subjects (16, 20):

- during the investigation of median nerve with the lead from abductor pollicis brevis muscle there will be low-voltage M-response in all stimulation points;
- during the investigation of ulnar nerve with the lead from abductor minimi muscle, abductor pollicis brevis muscle and 1<sup>st</sup> dorsal interosseal muscle there would be M-response of normal amplitude in all stimulation points.

Low-voltage M-response obtained from the abductor pollicis brevis muscle in absence of the median nerve injury (thenar muscle weakness and hypotrophy) requires exclusion of methodological mistakes (incorrect lead electrode placement, incorrect stimulation

point, insufficient stimulus power in all stimulation points) and RCA.

There are several clinical RCA cases described in the literature, which were determined by an accident or with other pathology (2, 21–24). Special attention draw those, when symptoms and clinical pattern imitate incurable disease such as amyotrophic lateral sclerosis.

Absence of complaints and neurologic symptoms combined with determined changes during investigation of left arm nerves will allow us to verify RCA type 1 (“ulnar” hand on the left side). Taking into account role of the ulnar nerve in the innervation of all hand muscles on the left the recommendations to follow certain motor stereotypes was given to the patient: limit flexion in the elbow joint more than 30–45°, not to lean on elbows and avoid compression in the area in order to prevent compression of the ulnar nerve at this level.

Berettini branch (BB) is interneural anastomosis between superficial sensor branches of the median and ulnar nerves at the hand level (25). In most cases the source of the sensor communicative branch is ulnar nerve (Fig. 2).

In 1999 Croatian anatomist investigated 100 hand preparations and determined the prevalence of this anastomosis as 81 % (26). Later Indian colleges proved this data (85 %) (27).

According to the G. P. Ferrari and A. Gilbert classification there are 4 types of BB depending on the location of communicative branch in the relation to the flexor retinaculum of the hand (28). Authors state that in in each 3 cases BB are located proximally to flexor retinaculum of the hand, that should be taken into account during endoscopic neurolysis of the median nerve in



carpal tunnel syndrome (29). Especially in carpal tunnel syndrome, which the most often compressive neuropathy, knowledge about BB are very relevant (30).

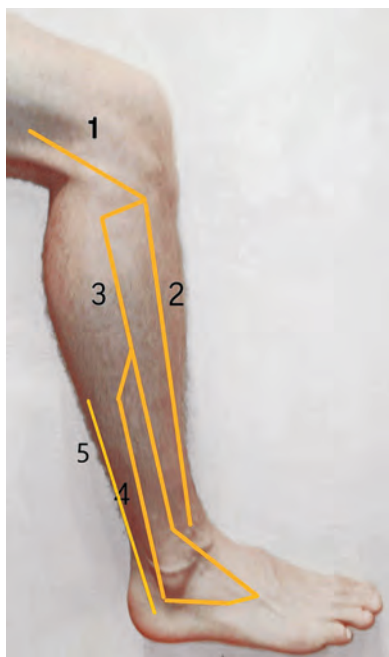
## Other interneural communications of the hand

There is an anastomosis on the dorsal surface of the hand between sensor portion of the radial nerve and dorsal sensor branch of the ulnar nerve, which is observed in half of the healthy subjects (31). In this type of anastomosis a great surface of skin of the dorsal hand surface is innervated by the superficial sensor portion of the radial nerve (1).

Kaplan anastomosis is rarely observed. It is a communication branch between sensor portion of the ulnar nerve and its superficial sensor branch on the palm. This anastomosis was described in works of P. Camper (1760) and much later – in works of E. B. Kaplan (1963) (32, 33).

## Types of interneural anastomoses of lower limbs

The most prevalent anastomosis of lower limbs is additional deep fibular nerve (ADFN), which is formed from superficial peroneal nerve or its branch, which together with deep motor branch of common fibular nerve innervate flexor pedis and provides sensory innervation to the lateral part of the foot (Fig. 3) (34).



**Fig. 3.** 1 – n. peroneus communis, 2 – n. peroneus profundus, 3 – n. peroneus superficialis, 4 – n. peroneus profundus accessorius, 5 – n. suralis

ADFN should be suspected in healthy subjects, when during the investigation of deep branch of common fibular nerve from the short flexor pedis in the 1<sup>st</sup> stimulation point (at the level of ankle joint), distal M-response is registered with 20 % or more lower amplitude, those obtained in the 2<sup>nd</sup> stimulation point (at the level of head of the fibula) (8, 34).

This neurographic pattern with all the confidence in the correct technique of the investigation (correct position of the active electrode, sufficient power of stimulus during stimulation in distal part, correct position of the stimulating electrode, etc.) require additional stimulation behind the lateral malleolus of the ankle joint. During mentioned additional stimulation in the presence of ADFN M-response is recorded. True amplitude of the distal M-response of studied deep branch of common fibular nerve will be equal to the sum of amplitude of distal and “additional M-responses and will be higher or equal to the M-response amplitude obtained in the 2<sup>nd</sup> stimulation point.

Prevalence of ADFN in the study of Rayegani S. M., Daneshtalab E., Bahrami M. H. (2011) was 12.2 % (17.9 % for bilateral and 82.1 % unilateral) (1).

## A clinical case

Our own experience supports an existence of additional deep fibular nerve. Local ethics committee approved the study. All the procedures were discussed with the patient and the informed consent was obtained prior to any study-specific procedures. Patient M., 1962 y.o.b. referred for help with neuropathic pain on the dorsal surface of the IV foot finger, that occurred after severe psychoemotional stress (sustained anaphylactic shock) and last for 4 recent years. Psychotherapy combined with submaximal doses of gabapentinoids and antidepressants caused only mild improvement (VAS 7–10). Cryoablation of superficial fibular nerve (under US guidance) was performed with anesthetic purposes. Effect was partial and mosaic (VAS 5–7). It was suspected, that this area has common innervation with other nerve. Selective blocks were performed with diagnostic purposes with local anesthetics (bupivacaine 0.25 % 3–4 ml/nerve) of deep fibular nerve, n. suralis and n. tibialis at the level of ankle joint. There was no anesthesia in the target zone. Then selective block (bupivacaine 0.25 % 3–4 ml/nerve) of superficial fibular nerve at the level of previous cryoablation was performed. There was no additional anesthesia in the area and the mosaic pattern remained. A conclusion about existence of additional deep fibular nerve was made.

Diagnostic block was performed under the US guidance with diagnostic purposes using 0.25 % 3 ml bupivacaine laterally to the superficial fibular nerve. Anesthesia of the target zone was obtained and cryodestruction was

performed in this point then (Fig. 4). Pain after cryoablation decreased to 3–4 VAS. Incomplete anesthesia can be explained by mechanisms central sensitization, which together with peripheral sensitization are main causes of neuropathic types of pain. Decrease of pain in more than 2 times was observed.

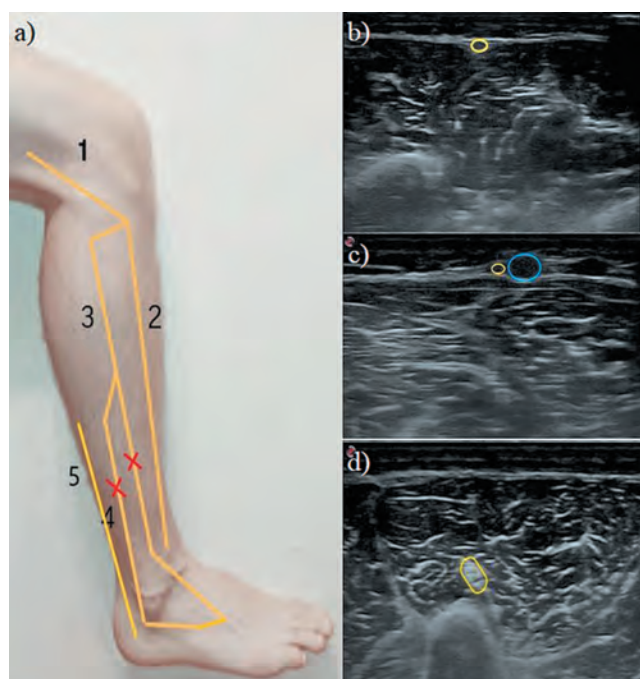


Fig. 4.

a – the point of performed cryodestruction:

1 – *n. peroneus communis*, 2 – *n. peroneus profundus*, 3 – *n. peroneus superficialis*, 4 – *n. peroneus profundus accessorius*, 5 – *n. suralis*;

b – *n. peroneus superficialis*;

c – *n. suralis* (orange), small saphenous vein (blue);

d – *n. peroneus communis*

There some described cases of the foot innervation by tibial nerve with the formation of so-called “tibial” foot (36, 37). But M. R. Magistris and A. Truffert, as well as J. Kimura doubt this innervation anomaly, indicating obvious methodological mistakes during the study conductance (1, 8, 38). There are studies, that describe anastomoses between facial and trigeminal nerves (39).

## Discussion

Existence of interneural anastomoses and innervation anomalies is obvious. They have different prevalence and can be unilateral as well as bilateral, which lead to changes of innervation zones of muscles and skin area, that normally have no manifestation.

Innervation anomalies are usually diagnosed by an accident and are usually ENMG findings with absence of

clinical data of neural pathology and data obtained as a result have complicated interpretation. Results of neurologic inspection is key to the diagnosis. So, ENMG parameters should always be compared to clinical pattern with adequate interpretation.

Presence of interneural anastomoses can misguide doctor during neurologic inspection in pathology and nerves injury, that participate in anastomosis, that is accompanied by atypical clinical and neurophysiological pattern, that make diagnostics more complicated (2).

Awareness of interneural anastomoses have some value in tunnel syndromes, trauma with nerve injury, pain medicine, some surgical interventions with conductive anesthesia.

Own experience supports existence of additional deep fibular nerve, that have impact on pain management.

## Conclusions

Existing data supports presence of interneural anastomoses. Our clinical experience shows, that presence of interneural anastomosis can significantly change and impact management and treatment of chronic pain in patients with neuropathic pain. Taking into account anatomical features of the patient, presence of interneural anastomosis could significantly change the peripheral block technique.

## References

1. D. A. Grishina, N. A. Suponeva, E. V. Pavlov, N. G. Savitskaya Anomalous innervations: variations and typical electromyography pattern. *Neuromuscular DISEASES* VOL. 6 2'2016. DOI: 10.17 650 / 2222–8721–2016–6–2–10–19
2. Saperstein D.S., King R.B. Motor neuron presentation of an ulnar neuropathy and Riche-Cannieu anastomosis. *Electromyogr Clin Neurophysiol* 2000;40(2):119–22. PMID: 10746189.
3. Sarikcioglu L., Sindel M., Ozkaynak S., Aydin H. Median and ulnar nerve communication in the forearm: an anatomical and electrophysiological study. *Med Sci Monit* 2003; 9(9):351–6. PMID: 1290925.
4. Felipe M.M., Telles F.L., Soares A.C. et al. Anastomosis between median nerve and ulnar nerve in the forearm. *J Morphol Sci* 2012;29(1):23–6.
5. Srinivasan R., Rhodes J. The median-ulnar anastomosis (Martin-Gruber) in normal and congenitally abnormal fetuses. *Arch Neurol* 1981;38(7):418–9. PMID: 645405.
6. Kimura J., Murphy M. J., Varda D. J., Van Allen M.W. Electrophysiological study of anomalous innervation of intrinsic hand muscles. *Trans Am Neurol Assoc* 1976;101:257–9. PMID: 1028254.
7. Kayamori R. Electrodiagnosis in Martin-Gruber anastomosis. *Nihon Seikeigeka Gakkai Zasshi* 1987;61(12):1367–72. PMID: 3450762.

8. Kimura J. Electrodiagnosis in diseases of nerve and muscle: principles and practice. 4<sup>th</sup> edn. Oxford: Oxford University Press, 2013. 1176 p.
9. Herrera E., Anaya C., Abril A.M. et al. Anastomosis Martin–Gruber: Aspecto anatómico y electrofisiológico. *Salud UIS* 2009;41(2):157–68.
10. Preston D.C., Shapiro B.E. Electromyography and neuromuscular disorders: clinical-electrophysiologic correlations. 3<sup>rd</sup> edn. Boston: Butterworth–Heinemann, 2013. 664 p.
11. Marras C., Midroni G. Proximal Martin–Gruber anastomosis mimicking ulnar neuropathy at the elbow. *Muscle Nerve* 1999;22(8):1132–5. PMID: 10417799.
12. Cho N.S., Kim D.H., Kim M.Y., Park B.K. Electrophysiological and ultrasonographic findings in ulnar neuropathy with Martin–Gruber anastomosis. *Muscle Nerve* 2013;47(4):604–7. DOI: 10.1002/mus.23607. PMID: 23463669.
13. Mikhaylyuk I.G. Martin–Gruber anastomosis and its clinical importance. *Klinitsist = The Clinician* 2015; (1):50–5. (In Russ.).
14. Stancic W.M.F., Burgic N., Mico W. vic W V. Marinacci communication. Case report. *J Neurosurg* 2000;92(5):860–2. PMID: 10794302.
15. Unver D.N., Uysal I.I., Seker M. The communications between the ulna and median nerves in upper limb. *J Neuroanatomy* 2009;8:15–9.
16. Kimura J., Ayyar D.R., Lippmann S.M. Electrophysiological verification of the ulnar to median nerve communications in the hand and forearm. *Tohoku J Exp Med* 1983;141(3):269–74. PMID: 6316583.
17. Meenakshi-Sundaram S., Sundar B., Arunkumar M.J. Marinacci communication: An electrophysiological study. *Clin Neurophysiology* 2003;114(12):2334–7. PMID: 14652092.
18. Golovchinsky V. Ulnar-to-median anastomosis and its role in the diagnosis of lesions of the median nerve at the elbow and the wrist. *Electromyogr Clin Neurophysiol* 1990;30(1):314. PMID: 2303003.
19. Boland R.A., Krishnan A.V., Kiernan M.C. Riche–Cannieu anastomosis as an inherited trait. *Clin Neurophysiol* 2007;118(4):770–5. PMID: 17317302.
20. Dimitru D., Walsh N.E., Weber C.F. Electrophysiologic study of the Riche–Cannieu anomaly. *Electromyogr Clin Neurophysiol* 1988;28(1):27–31. PMID: 3168913.
21. Gozkea E., Gurerb R., Gurbuzera N. Riche–Cannieu Anastomosis: A Case Report. *J Med Cases* 2012; 3(3):195–6.
22. Tamagawa C., Shiga K., Ohshima Y. et al. Riche–Cannieu anastomosis and a paradoxical preservation of thenar muscles in carpal tunnel syndrome: a case report. *No To Shinkei* 2004;56(1):53–8. PMID: 15024830.
23. Refaiean M., King J.C., Dumitru D., Cuether A.C. Carpal tunnel syndrome and the Riche–Cannieu anastomosis: electrophysiologic findings. *Electromyogr Clin Neurophysiol* 2001;41(6):377–82. PMID: 11680862.
24. Rovers J.M., Brekelmans G.J., Visser L.H. Psoas-hamate hiatus syndrome in a patient with Riche–Cannieu anastomosis. *BMJ Case Rep* 2013. DOI: 10.1136/bcr-2013-008601. PMID: 23519507.
25. Bozkurt M.C. Berrettini branch. *J Neurosurg* 2011; 114(1φ):276. DOI: 10.3171/2010.7.JNS101115. PMID: 20690808.
26. Stancic W.M.F., Mico W. vic W V., Potocnjak M. The anatomy of the Berrettini branch: implications for carpal tunnel release. *J Neurosurg* 1999;91(6):1027–30. PMID: 10584850.
27. Yoganandham J., Hannah Sugirthabai R.R., Thotakura B. et al. A study on the communications of median nerve with musculo cutaneous and ulnar nerves. *Intern J Resear Health Sci* 2014;2(2):481–7.
28. Ferrarri G.P., Gilbert A. The superficial anastomosis on the palm of the hand between the ulnar and median nerves. *J Hand Surg Br* 1991;16(5):511–4. PMID: 1791361.
29. Chen L., Duan X., Huang X. et al. Effectiveness and safety of endoscopic versus open carpal tunnel decompression. *Arch Orthop Trauma Surg* 2014;134(4): 585–93. DOI:10.1007/s00402-013-1898-z. PMID: 24414237.
30. Filatova E.S. Carpal tunnel syndrome in rheumatic diseases. *Nervnomyshechnye bolezni = Neuromuscular Diseases* 2014;(2):27–31. (In Russ.) DOI: <http://dx.doi.org/10.17650/2222-8722014-0-2-27-31>.
31. Loukas M., Louis R.G., Wartmann C.T. et al. The clinical anatomy of the communications between the radial and ulnar nerves on the dorsal surface of the hand. *Surg Radiol Anat* 2008;30(2):85–90. DOI: 10.1007/s00276-008-0304-y. PMID: 18217183.
32. Paraskevas G., Gekas C., Tzaveas A. et al. Kaplan anastomosis of the ulnar nerve: a case report. *J Med Case Reports* 2008;2:107. DOI:10.1186/1752-1947-2-107. PMID: 18412973.
33. Hankins C.L., Flemming S. A variant of Kaplan’s accessory branch of the dorsal cutaneous branch of the ulnar nerve: a case report and review of the literature. *J Hand Surg Am* 2005;30(6):1231–5. PMID: 16344181.
34. Rayegani S.M., Daneshmandi E., Bahrami M.H. et al. Prevalence of accessory deep peroneal nerve in referred patients to an electrodiagnostic medicine clinic. *J Brachial Plex Peripher Nerve Inj* 2011;6(1):3. DOI: 10.1186/1749-7221-6-3. PMID: 21740542.
35. Tzika M., Paraskevas G.K., Kitsoulis P. The accessory deep peroneal nerve: a review of the literature. *Foot (Edinb)* 2012;22(3):232–4. DOI: 10.1016/j.foot.2012.05.003. PMID: 22795551.
36. Linden D., Berlitz P. The intrinsic foot muscles are purely innervated by the tibial nerve (“all tibial foot”) – an unusual innervation anomaly. *Muscle Nerve* 1994;17(5):560–1. PMID: 8159110.
37. Yamashita M., Mezaki T., Yamamoto T. “All tibial foot” with sensory crossover innervation between the tibial and deep peroneal nerves. *J Neurol Neurosurg Psychiatry* 1998;65:798–9. PMID: 9810964.
38. Magistris M.R., Truffert A. Extensor digitorum brevis innervated by the tibial nerve (“all tibial foot”): anomalous innervation or technical pitfall? *Muscle Nerve* 1997;20(7):906–8. PMID: 9179169.



39. Gelashvili O.A., Dulcina M.N., Sreseli A.G. Features of branching uniceramic branches of the facial nerve in the adult. Samara state medical University. Bulletin of Medical Internet Conferences 2017. Volume 7. Issue 12.
40. Thompson G. E., Rorie D. K. Functional anatomy of the brachial plexus sheaths // Anesthesiology. 1983; 59: 117122.

**Аномалії іннервації та міжневральні анастомози:  
це клінічно значимо чи ні?**

Дмитрієв Д. В., Дмитрієв К. Д., Лисак Є. В.

**Резюме.** Невдала блокада може бути одним із побічних явищ проводникової анестезії. Є ситуації, коли при, здавалось би, ідеальній техніці блокади, правильно підібраному препараті та його дозуванні, ад'юванті – ефект блокади не досягається (або з'являється так звана мозаїчна блокада). Необхідно пам'ятати про атипичні чи аномальні розгалуження нервів, можливі міжневральні анастомози, як імовірну причину невдалих блокад. Інформацію про найпоширеніші типи анастомозів верхніх та нижніх кінцівок наведено у статті. Знання щодо можливих змін нормальної іннервації може забезпечити розуміння неефективності деяких блокад, знизити кількість помилок в інтерпретації даних, отриманих під час електронейроміографії, покращити розуміння патерну клінічних змін при ушкодженні периферичних нервів, що утворюють анастомоз.

**Ключові слова:** міжневральні анастомози, аномалії іннервації, проводникова анестезія, електронейроміографія.

**Аномалии иннервации и межневральные анастомозы:  
это клинически значимо или нет?**

Дмитриев Д. В., Дмитриев К. Д., Лысак Е. В.

**Резюме.** Неудачная блокада может быть одним из побочных явлений проводниковой анестезии. Есть ситуации, когда при, казалось бы, идеальной технике блокады, правильно подобранному препарату и его дозировке, адъюванте – эффект блокады не достигается (или появляется так называемая мозаичная блокада). Необходимо помнить об атипичных разветвлениях нервов, возможных межневральных анастомозах как вероятной причине неудачных блокад. Информация о наиболее распространённых типах анастомозов верхних и нижних конечностей приведена в статье. Знания о возможных изменениях нормальной нервной иннервации может обеспечить понимание неэффективности некоторых блокад, снизить количество ошибок в интерпретации данных, полученных во время электронейромиографии, улучшить понимание паттерна клинических изменений при повреждении периферических нервов, образующих анастомоз.

**Ключевые слова:** межневральные анастомозы, аномалии иннервации, проводниковая анестезия, электронейромиография.

Увага! Купон -50% для перших 50 підписників. Поспішайте!

pmj50 online

# CACTUS

Conference of Acute and Chronic pain  
Treatment with UltraSound navigation

COMING SOON

6-7 November 2020

[https://uaratb.org/cactus\\_fall](https://uaratb.org/cactus_fall)

